

Recurrent stroke from paradoxical embolism in a case with hereditary hemorrhagic telangiectasia

พ.ท. ศักดิ์สิทธิ์ ศักดิ์สูง

พ.ท.หญิง ศันสนีย์ แสงวนิช

พ.อ. เฉษฐา อุดมมงคล

แผนกประสาทวิทยา กองอายุรกรรม

และศูนย์โรคหลอดเลือดสมอง

โรงพยาบาลพระมงกุฎเกล้า

Saksit Saksoong, MD

Sansanee Saengwanich, MD

Chesda Udommongkol, MD

Department of Medicine, Stroke Center,
Phramongkutklao Army Hospital

SAKSIT SAKSOONG, MD

Neurovascular and neurosonology fellow

Department of Neurology,

Phramongkutklao Army Hospital

Rajvithee Road, Rajthewee,

Bangkok Thailand 10400

Tel. +66-2-3547600 ext. 93027

Fax. +66-2-6444635

Email: saksit2525@gmail.com

SANSANEE SAENGWANICH, MD

Neurologist, Department of Neurology,

Phramongkutklao Army Hospital

Rajvithee Road, Rajthewee,

Bangkok Thailand 10400

Tel. +66-2-3547600 ext. 93027

Fax. +66-2-6444635

Email: abple8811@hotmail.com

CHESDA UDOMMONGKOL, MD PhD

Head of Neurology,

Phramongkutklao Army Hospital

Rajvithee Road, Rajthewee,

Bangkok Thailand 10400

Tel. +66-2-3547600 ext. 93027

Fax. +66-2-6444635

Email: chesda_udommongkol@yahoo.com

Rendu Osler Weber or Hereditary Hemorrhagic Telangiectasia (HHT) is an autosomal dominant genetic disorder causing abnormal development of vasculature characterized by telangiectases and arteriovenous malformations of specific organs. The most common presentation of HHT is epistaxis; however ischemic stroke occasionally occurs due to paradoxical shunt such as pulmonary arteriovenous malformation (PAVM). We reported a 37-year-old woman presenting with recurrent ischemic stroke as a result of paradoxical emboli from PAVMs. The patient was brought to emergency department and the examination revealed left facial palsy and left hemiplegia. The CT angiography demonstrated complete occlusion of the distal right M1 MCA. Transcranial Doppler showed positive microbubble examination with suspected extracardiac shunts corresponding with positive bubble test from transesophageal echocardiogram. Pulmonary angiography demonstrated 3 PAVMs and the shunts were successfully embolized. The patient was disabling due to large volume of the right MCA infarction. (*J Thai Stroke Soc.* 2017; 16 (3): 49–54.)

Keywords: Rendu Osler Weber, hereditary hemorrhagic telangiectasia, pulmonary arteriovenous malformation, recurrent ischemic stroke

Rendu Osler Weber or Hereditary Hemorrhagic Telangiectesia (HHT) is a rare autosomal dominant genetic disorder causing multiple vascular dysplasia such as telangiectasia on mucosal area. Patients may suffer from several manifestations resulting from vascular defects including nose bleeding (epistaxis) which is the most common symptom, and gastrointestinal bleeding.¹ Ischemic stroke is one of vascular manifestations accounting of 15%² caused by paradoxical emboli via shunting from extracardiac arteriovenous malformation in lungs, liver, or pancreas.³ Clots in the venous system are able to bypass the pulmonary capillary system through those shunts and result in embolism into terminal organs such as cerebral hemispheres.

Extracardiac or intracardiac shunts can be effectively detected by contrast-enhanced transcranial Doppler study (TCD), and the TCD gains as high as 100% sensitivity comparable with transthoracic contrast echocardiography (TTCE)^{4,5}. Microbubbles in agitated saline are frequently used as contrast media and those microemboli give rise to distinctive characterized Doppler signals in both examinations.

Case Report

A 37year-old Thai woman presented with sudden left hemiparesis while engaging leisure activity. She had two episodes of non-disabling ischemic stroke. In the first attack, 6 year earlier, the patient presented with acute dysathria and weakness on her right arm. Diagnostic work up for young onset ischemic stroke was done including transthoracic echocardiogram, Electrocardiography, VDRL, TPHA, Anti-HIV, thrombophilia, and inflammatory vasculitis work up. All of the test results appeared normal. The MRI/MRA scan demonstrated a small segmental caliber of the

basilar artery with bilateral thalamic infarction. The diameter of the basilar artery was later recovered, therefore reversible cerebral vasoconstriction syndrome was initially suspected. After the ischemic attack, she was then given an antiplatelet for secondary prophylaxis. 4 years later, she experienced acute right facial palsy with a complaint of right sided hemiparesthesia. She was diagnosed with recurrent ischemic stroke and her deficits eventually improved to normal state within a few months.

One day earlier, the patient had bleeding per nose in the morning concurrently with bilateral tensed headache.

On this admission, the patient abruptly experienced dysathria and left sided hemiparesis with facial palsy approximately 40 minutes earlier. At emergency department, she became drowsy. Physical examination revealed bleeding per nose with suspected telangiectasia at nasal septum, tongue and both lips. Left hemiplegia was observed and her NIHSS score was 13. A large right middle cerebral artery (MCA) infarction was preliminary suspected. The CT scan showed a dense MCA sign on the right MCA and old infarctions on both thalami owing to previous stroke.

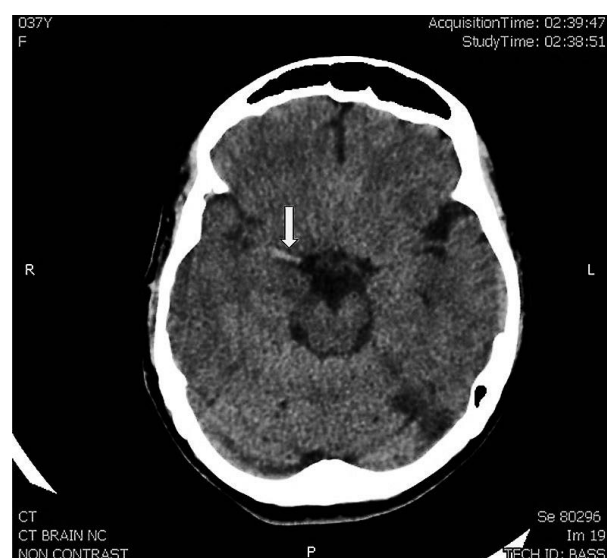


Figure 1: Axial non contrast CT brain: dense MCA signs (cord sign) on the right MCA (arrow).

Intravenous thrombolysis was not given because of active recurrent epistaxis within one month. Following CT angiography demonstrated an obvious distal right M1 MCA occlusion.

Mechanical thrombectomy was undergone and the procedure achieved recanalization. The

decompressive craniectomy was done to treat severe cerebral swelling and she later received bed-side rehabilitation. Causes of stroke in the young were then re-evaluated. Results from all blood tests for hypercoagulable states and inflammatory vasculopathy were normal.

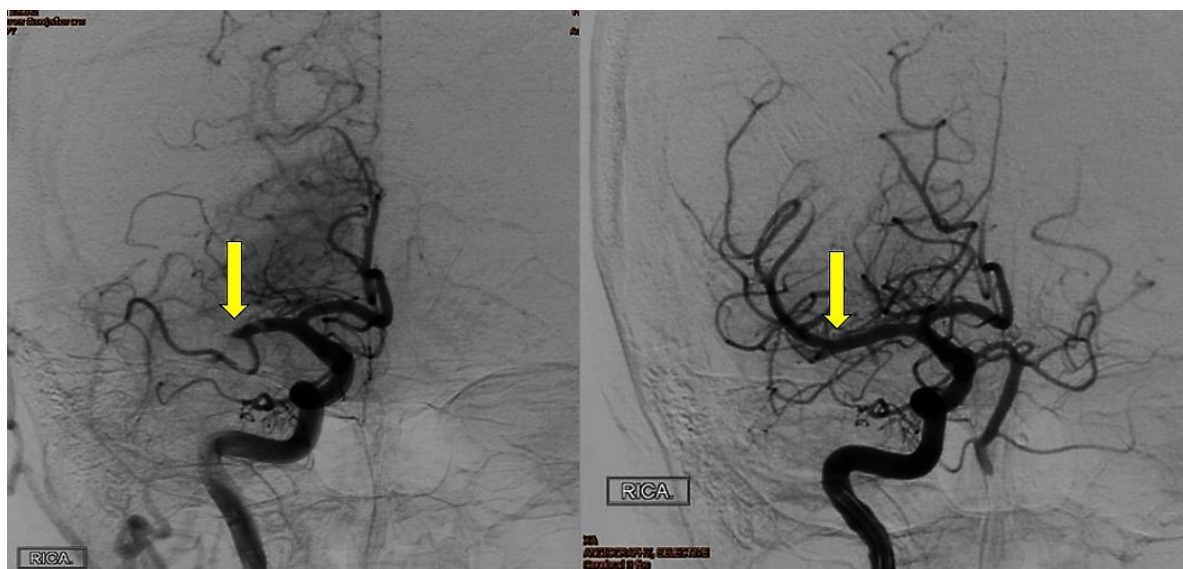

Figure 2: DSA: left image showed a total occlusion of the distal right M1 MCA and right image showed recanalization after an endovascular therapy.

Transcranial Doppler was done and the study revealed positive bubble test at a period of

time longer than 10 cardiac cycles after agitated saline was administered.

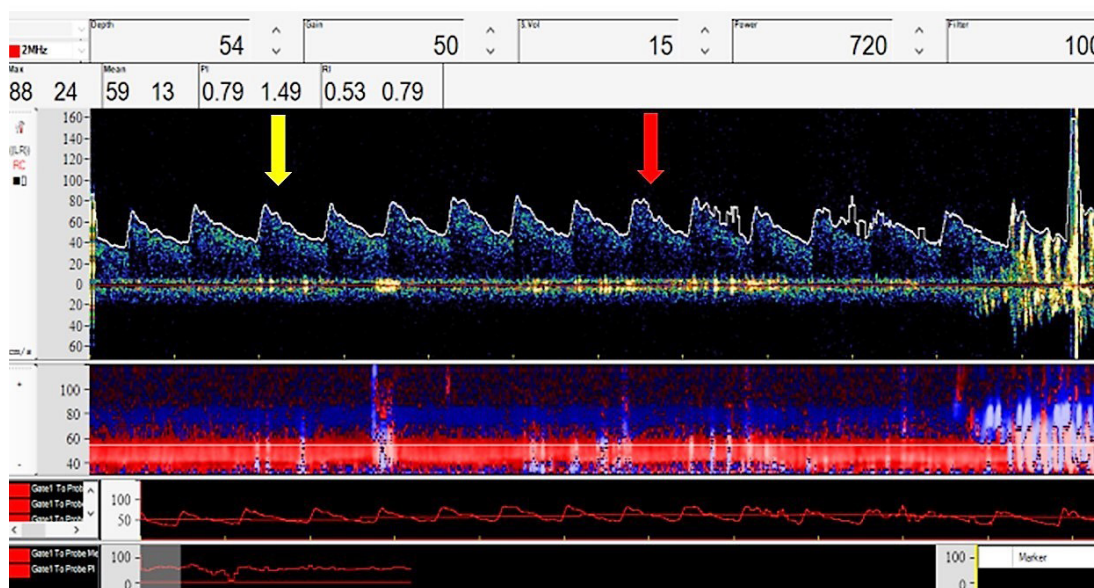


Figure 3: TCD study demonstrated time of bubble injection (yellow arrow), time of Valsalva initiation (red arrow) and embolic signals appeared at a time longer than 10 cardiac cycles after injection

Regarding previous study by using echocardiography in detecting right-to-left shunt in HTT, if the bubbles contrast were detected within 3 cardiac cycles after agitated saline injection, intracardiac shunt should be considered. On the other hand, if the bubbles were detected following 8 cardiac cycles or longer time after

the contrasted injection, extracardiac shunt should be suspected.⁵

Transoesophageal echocardiogram was done and similarly confirmed a positive bubble test. Extracardiac shunt was then highly suspected.

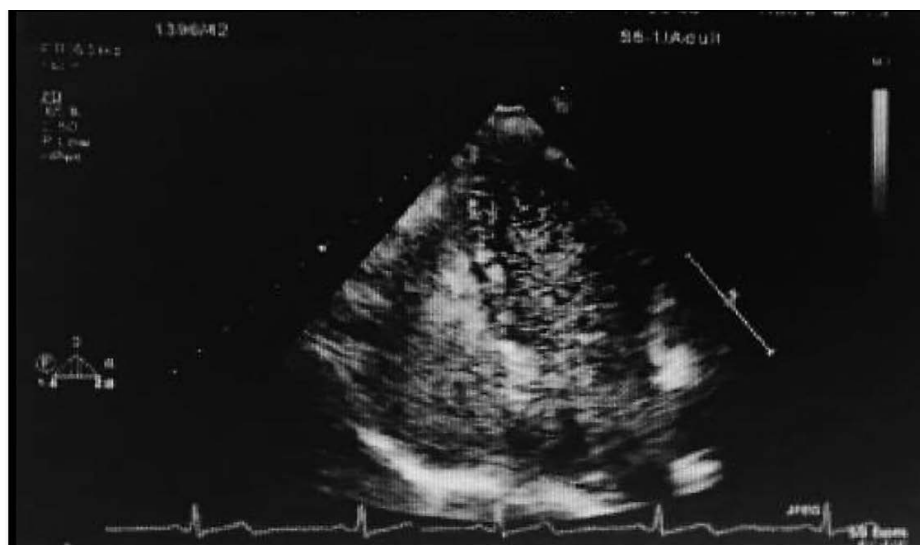


Figure 4: transesophageal echocardiogram revealed numerous microbubbles in the left ventricle.

The interventionist was consulted for angiographic study of the thoracic. The pulmonary angiography revealed 3 pulmonary arteriovenous malformations at left lower lung in which were later successfully embolized by the interventionist.

The patient symptoms remained stable. She was disabling due to large left MCA infarction. The antiplatelet was continued and she has not been suffering another recurrent episode until present.

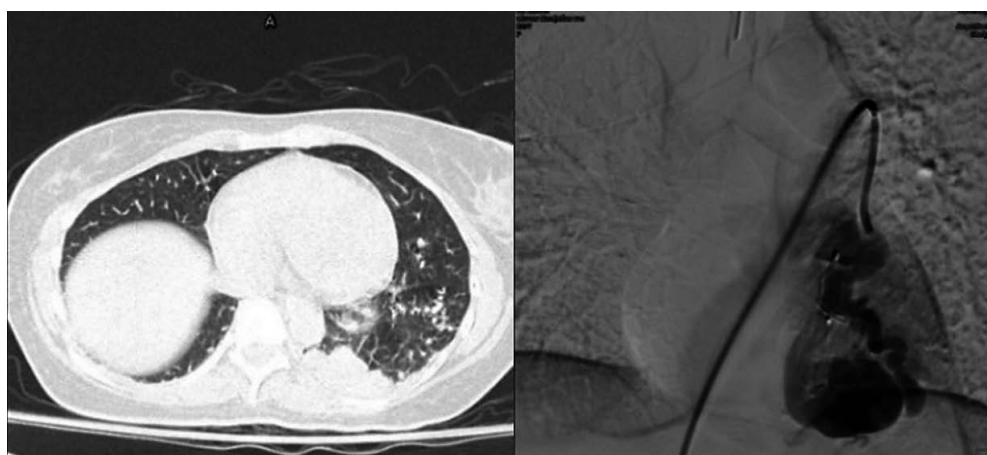


Figure 5: Left, CT angiogram of chest demonstrated abnormal dilated vascular structure in the left basal lung. Right; Angiographic study showed arteriovenous malformations in the left lung.

Discussion

Diagnosis of hereditary hemorrhagic telangiectasia is challenging and essential. Our patient had experienced acute ischemic events prior to this visit. She had not been diagnosed of HHT until current visit which eventually resulted in more severe disability. Routine worked up for routine unusual cause in young onset of stroke should be strictly monitored, for example, bubble or contrasted echocardiography or bubble transcranial Doppler study. To diagnose Osler Weber Rendu disease, we use Curacao clinical criteria which are as follows⁶

1. Epistaxis
2. Telangiectasias–characteristic sites include lips, oral cavity, fingers and nose;
3. Visceral lesions including gastrointestinal, hepatic, PAVMs, cerebral AVMs (CAVMs) or spinal AVMs
4. Family history with a first-degree relative with HHT

Presence of three or more clinical criteria makes a definite diagnosis while two criteria is a possible diagnosis.

Our patient had three out of four criteria: recurrent epistaxis, mucosal telangiectasis and established pulmonary AVMs, whereas family history could not be confirmed. Though, epistaxis is the most common presentation affecting about 85–90% of patients.⁷ History of bleeding nose had not been documented during the first 2 visits of ischemic events in our patient. In study concerning delayed in diagnosis of HHT, an ischemic stroke was found as the onset presentation of disease in only 3/233 (1.3%) while epistaxis alone occurred 202/233 (86.7%).⁸

Consideration is given to screening for PAVMs in all patients with HHT who present with neurological manifestation.^{9,10} Therefore,

Bubble study in echocardiogram or transcranial Doppler ultrasound should be performed to detect right to left shunting in such patient.

Conclusion

Transcranial Doppler with bubble study is useful in detecting right to left shunting and the examination helps distinguish intracardiac shunt and extracardiac shunt with high sensitivity comparable to bubble echocardiography.⁵

Reference

1. McDonald J, Bayrak–Toydemir P, Pyeritz RE. Hereditary hemorrhagic telangiectasia: An overview of diagnosis, management, and pathogenesis. *Genetics In Medicine*. 2011;13:607.
2. Begbie ME, Wallace GM, Shovlin CL. Hereditary haemorrhagic telangiectasia (Osler–Weber–Rendu syndrome): a view from the 21st century. *Postgrad Med J*. 2003;79(927):18–24.
3. Román G, Fisher M, Perl DP, Poser CM. Neurological manifestations of hereditary hemorrhagic telangiectasia (Rendu–Osler–Weber disease): report of 2 cases and review of the literature. *Ann Neurol*. 1978;4(2):130–44.
4. Teague SM, Sharma MK. Detection of paradoxical cerebral echo contrast embolization by transcranial Doppler ultrasound. *Stroke*. 1991;22(6):740–5.
5. Manawadu D, Vethanayagam D, Saqqur M, Derksen C, Choy J, Khan K. Screening for right-to-left shunts with contrast transcranial Doppler in hereditary hemorrhagic telangiectasia. *Stroke*. 2011;Stroke.
6. Shovlin CL, Guttmacher AE, Buscarini E, Faughnan ME, Hyland RH, Westermann CJ,

- et al. Diagnostic criteria for hereditary hemorrhagic telangiectasia (Rendu-Osler-Weber syndrome). *Am J Med Genet.* 2000;91(1):66-7.
7. AAssar OS, Friedman CM, White RI. The natural history of epistaxis in hereditary hemorrhagic telangiectasia. *Laryngoscope.* 1991;101(9):977-80.
8. Pierucci P, Lenato GM, Suppressa P, Lastella P, Triggiani V, Valerio R, et al. A long diagnostic delay in patients with Hereditary Haemorrhagic Telangiectasia: a questionnaire-based retrospective study. *Orphanet J Rare Dis.* 2012;7:33.
9. Kjeldsen AD, Oxhøj H, Andersen PE, Elle B, Jacobsen JP, Vase P. Pulmonary arteriovenous malformations: screening procedures and pulmonary angiography in patients with hereditary hemorrhagic telangiectasia. *Chest.* 1999;116(2):432-9.
10. Faughnan ME, Palda VA, Garcia-Tsao G, Geisthoff UW, McDonald J, Proctor DD, et al. International guidelines for the diagnosis and management of hereditary haemorrhagic telangiectasia. *J Med Genet.* 2011;48(2):73-87.

บทคัดย่อ

Rendu Osler Weber หรือ Hereditary Hemorrhagic Telangiectesia (HHT) เป็นโรคทางพันธุกรรมที่ส่งทอดแบบยีนเด่น ทำให้เกิดความผิดปกติในการพัฒนาหลอดเลือดและทำให้เกิดหลอดเลือดโป่ง และการสร้างการเชื่อมต่อผิดปกติของหลอดเลือดแดงและดำ ในอวัยวะต่างๆ อาทิเช่น ปอด ตับ หรือตับอ่อน อาการแสดงที่พบได้บ่อยที่สุดคือเลือดกำเดาออก การที่มีการเชื่อมต่อของหลอดเลือดแดงและดำผิดปกติโดยเฉพาะในปอด ทำให้เกิดลิ่มเลือดที่ผ่านเข้าไปยังห้องหัวใจด้านซ้ายได้โดยตรงและทำให้เกิดหลอดเลือดสมองอุดตัน โดยหากไม่ได้รับการแก้ไขทำให้เกิดหลอดเลือดสมองอุดตันกลับเป็นซ้ำได้

ผู้นิพนธ์รายงานผู้ป่วยหญิง 37 ปี ที่เป็นโรคหลอดเลือดสมองแบบกลับเป็นซ้ำ ในครั้งที่สามมีอาการเลือดกำเดาออก 1 เดือนเป็นๆหายๆ ร่วมกับอาการอ่อนแรงแขนขาข้างซ้ายจับปล้นและใบหน้าเบี้ยวข้างซ้าย จากผลตรวจทางรังสีพบการอุดตันส่วนปลายของหลอดเลือดสมอง MCA ข้างขวาและได้รับการรักษาด้วยการสวนหลอดเลือด การตรวจหลอดเลือดสมองด้วยคลื่นเสียงความถี่สูงร่วมกับฟองอากาศช่วยวินิจฉัยสาเหตุภาวะการเชื่อมต่อของเส้นเลือดแดงและดำผิดปกติภายนอกหัวใจ ผลการตรวจหลอดเลือดทางรังสีพบการเชื่อมต่อของเส้นเลือดแดงและดำผิดปกติในปอด และได้ทำการอุดเส้นเลือดผิดปกติ

คำสำคัญ: Rendu Osler Weber, hereditary hemorrhagic telangiectasia, pulmonary arteriovenous malformation, recurrent ischemic stroke, TCD bubble test, right to left shunt